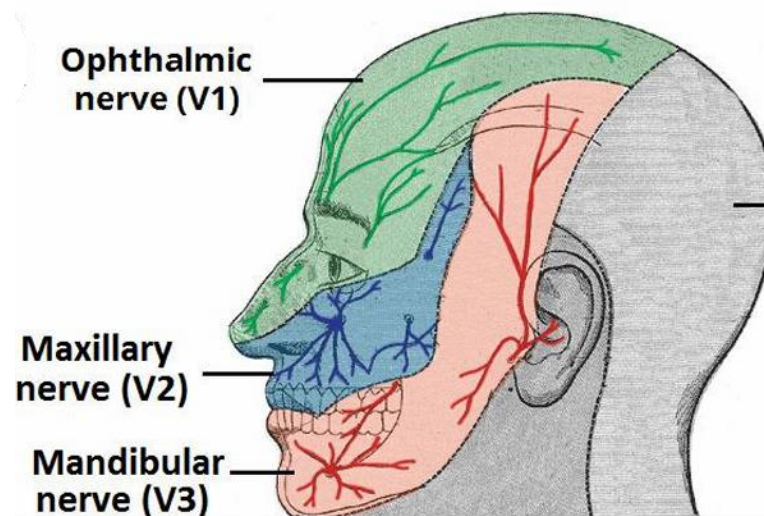
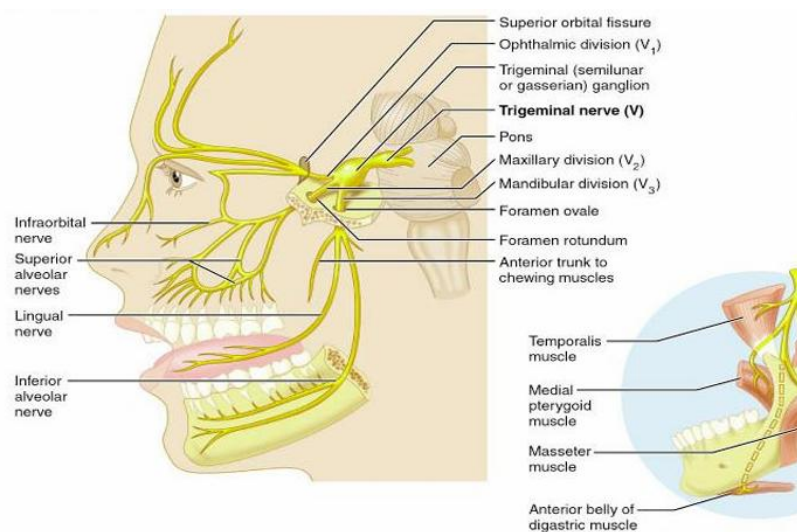


# Trigeminal System

## Trigeminal Nerve (CN V)

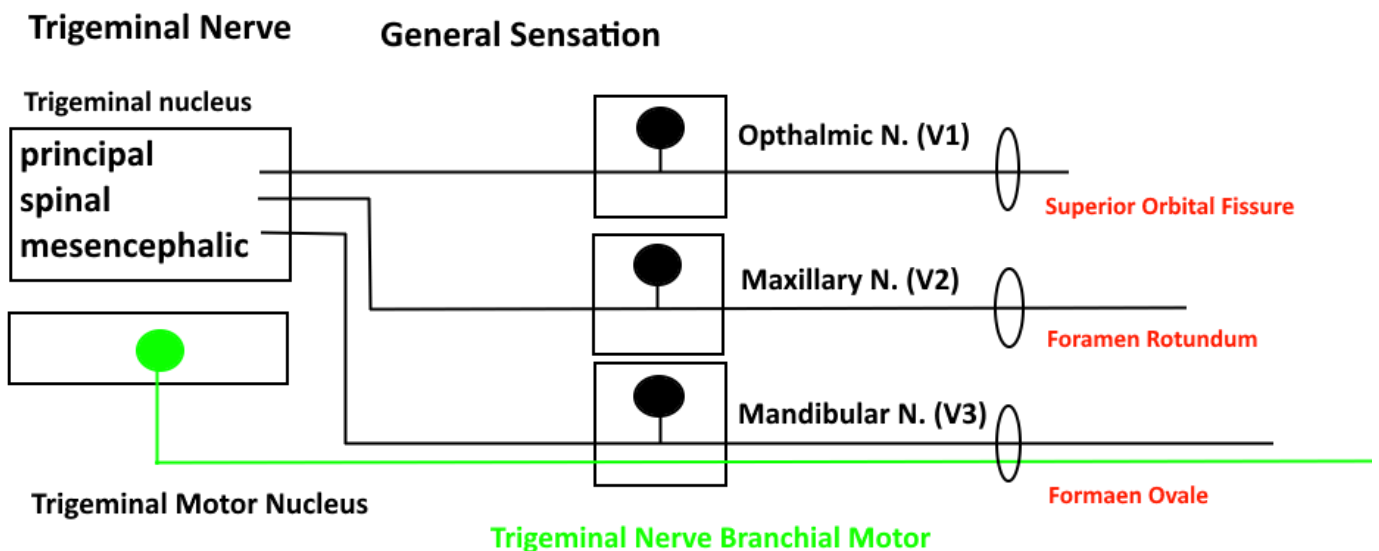
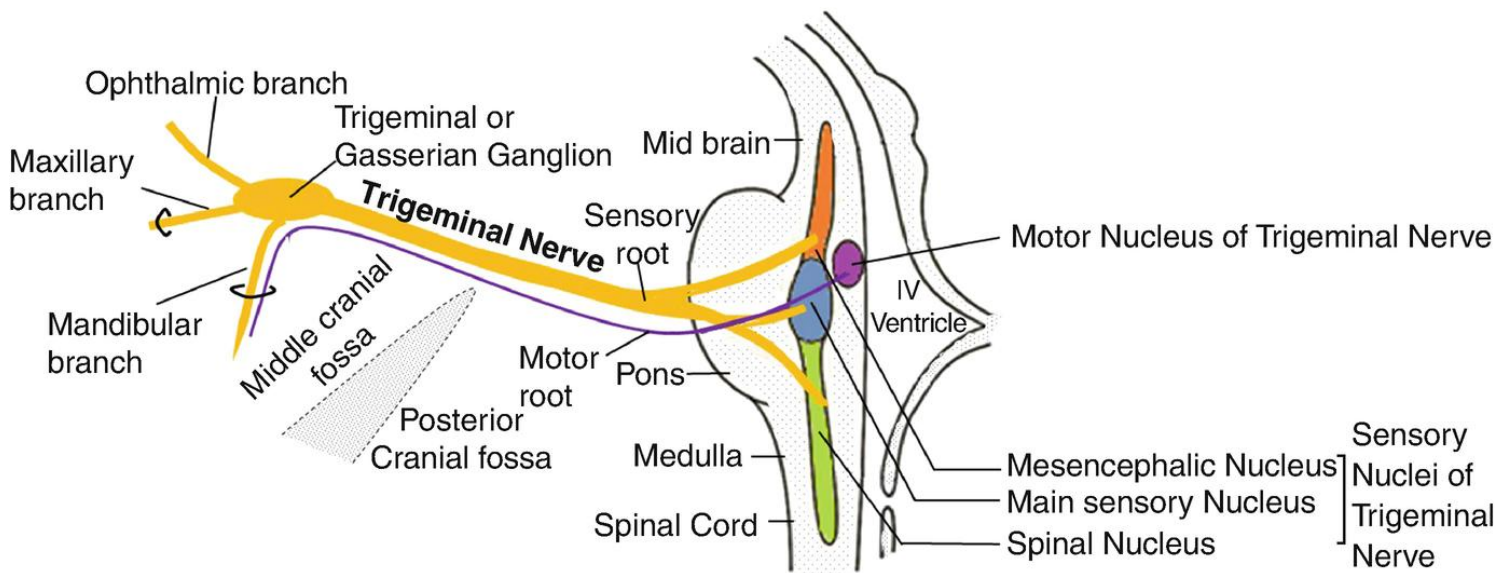
- It is the **fifth** cranial nerve.
- It is the **largest** cranial nerve.
- It is a **mixed** nerve (sensory, motor & parasympathetic).

<b>Sensory</b>	The three terminal branches of CN V innervate the <b>skin, mucous membranes and sinuses</b> of the face.	
<b>Motor</b>	<b>Only mandibular</b>	Innervates the <b>muscles of mastication</b> : (Medial & lateral pterygoid, masseter and temporalis).
		It supplies <b>1st pharyngeal arch muscles</b> : (Anterior belly of digastric, mylohyoid, tensor palate and tensor tympani).
<b>Parasympathetic</b>	The post-ganglionic neurons of parasympathetic ganglia travel with branches of the trigeminal nerve.	
<b>N.B.</b> CN V is NOT part of the cranial outflow of PNS supply.		



## Nuclei of the Trigeminal Nerve

Nuclei	Location	Function
Mesencephalic nucleus	Midbrain	First-order neuron for proprioception ( <b>Kinesthesia</b> ) from <b>muscles of head</b> & temporomandibular joint ( <b>TMJ</b> ).
Main sensory nucleus (Principal nucleus)	Upper pons	Mediates <b>discriminative touch and pressure</b> from same side.
Spinal nucleus	Upper pons Medulla C2 segment	Mediates <b>pain and temperature</b> from same side.
Motor nucleus	Upper pons	Forms motor root of CN V. Supplies <b>muscles of the 1st pharyngeal arch</b> .

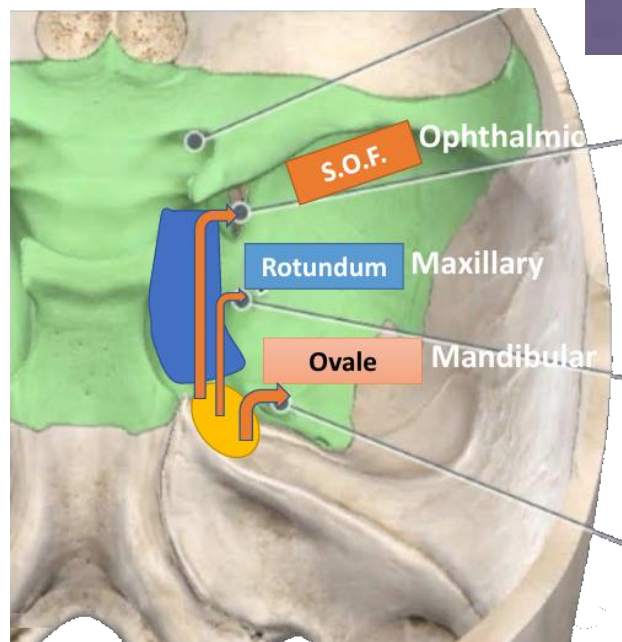
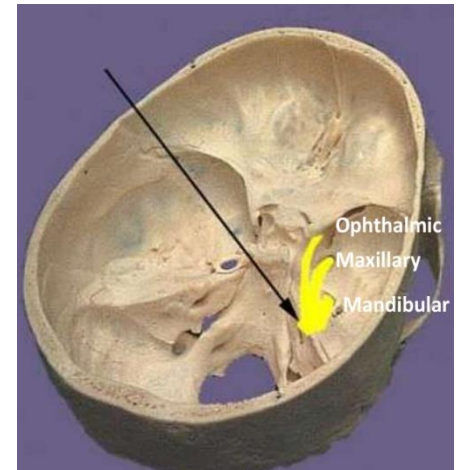
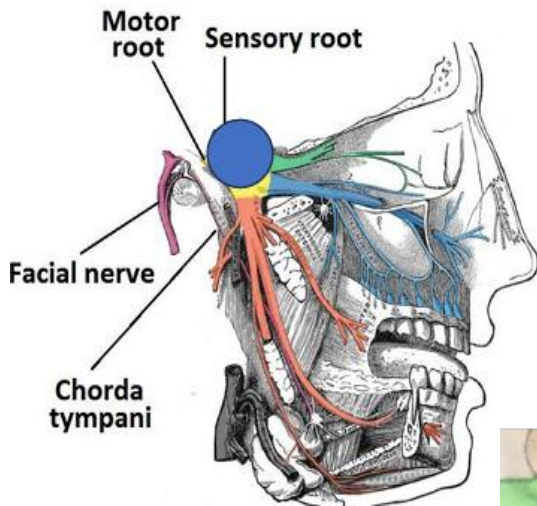


## Intracranial Course of CN V

- In the **middle cranial fossa**, the sensory root expands into the **trigeminal ganglion**.
- The trigeminal ganglion lies within a pouch of dura mater called **Cavum trigeminale**.
- Divided into **3 branches** which travel through the cavernous sinus.
- The **motor root** of the trigeminal nerve is situated **below the sensory ganglion**.

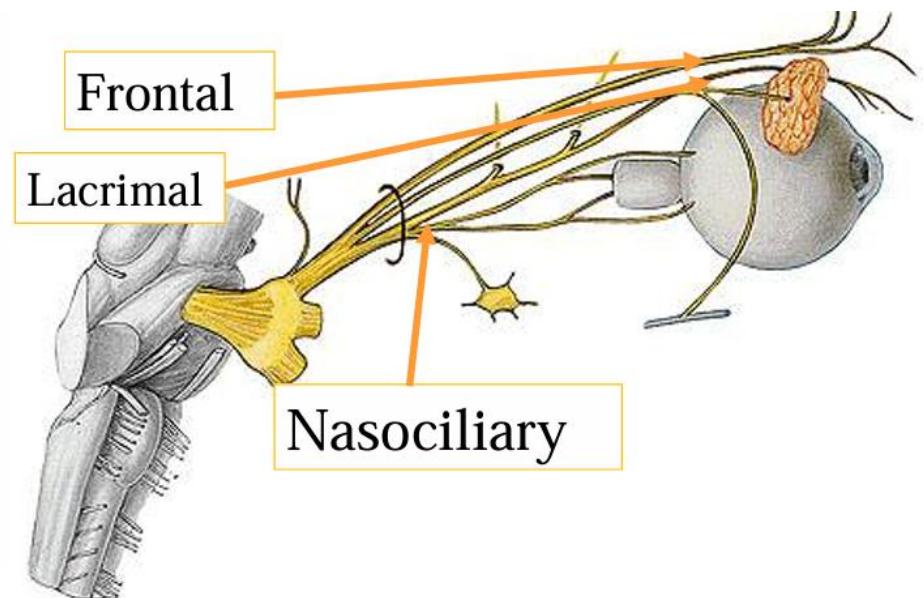
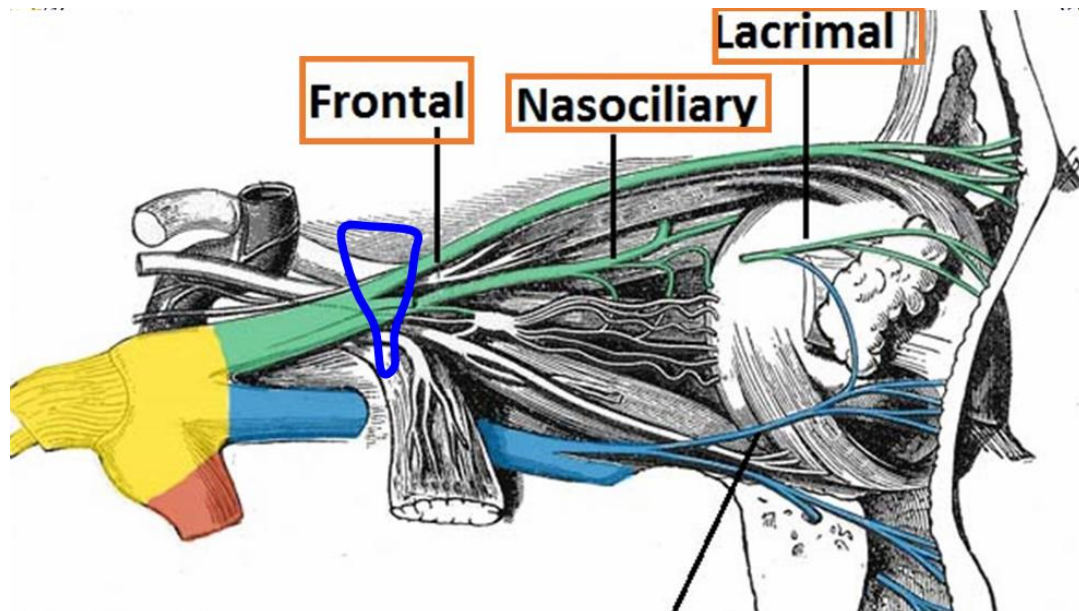
## Extracranial Course of CN V

Division	Exiting from
Ophthalmic nerve (V1)	Superior Orbital Fissure.
Maxillary nerve (V2)	Foramen Rotundum.
Mandibular nerve (V3)	Foramen Ovale; entering the infra-temporal fossa.
N.B.	The motor root passes inferiorly to the sensory root. Its fibers are <b>only distributed to the mandibular division</b> .



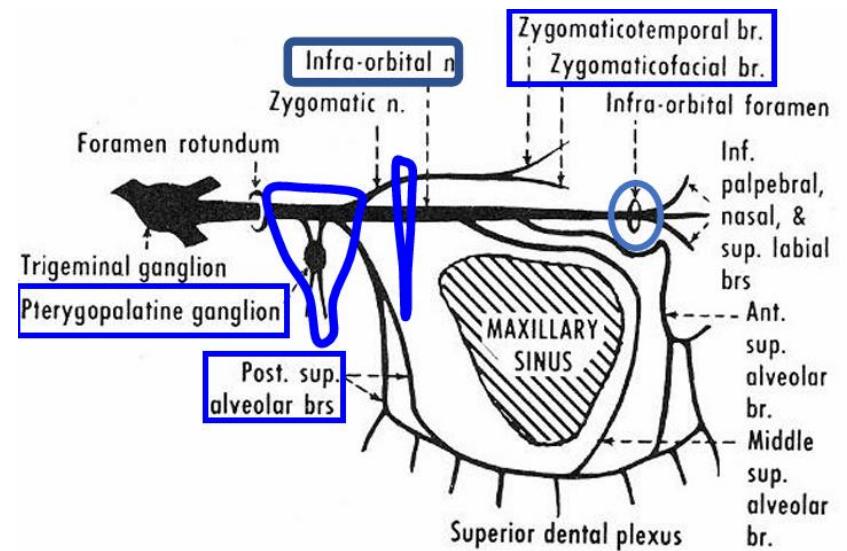
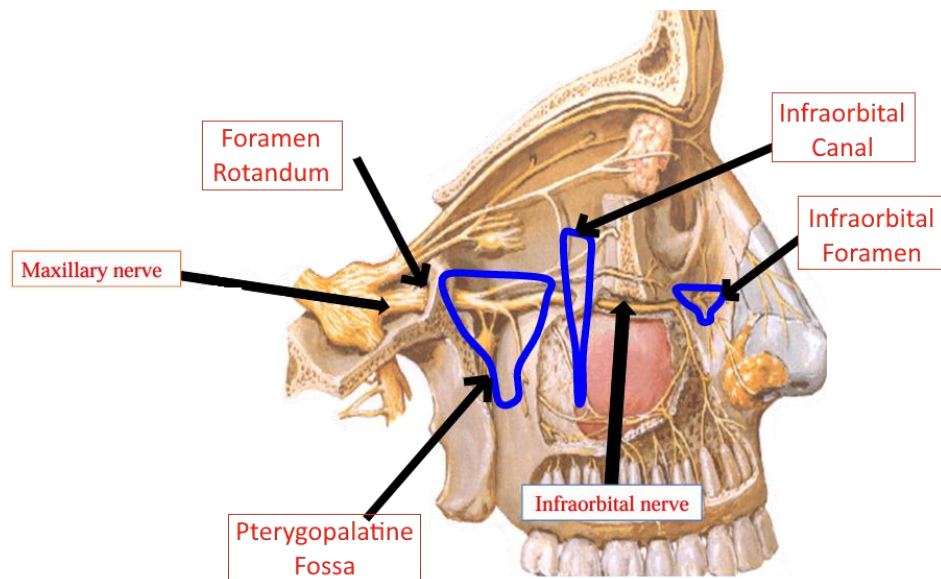
## Divisions of CN V (Ophthalmic N. [VI])

Size	Superior & <b>Smallest</b> division	
Type	Sensory Nerve	
Pathway	Passes forward in the lateral wall of the <u>cavernous sinus</u> , <u>below the oculomotor and trochlear nerves</u> . (Cavernous sinus → Superior orbital fissure → Orbit). Before entering the orbit by the superior orbital fissure, it divides into:	
Branches	Frontal N. (largest)	Skin of forehead
	Lacrimal N. (smallest)	Lacrimal gland (sensory fibers)
	Nasociliary N. (Intermediate)	Eye, nasal cavity, dorsal part of the nose.



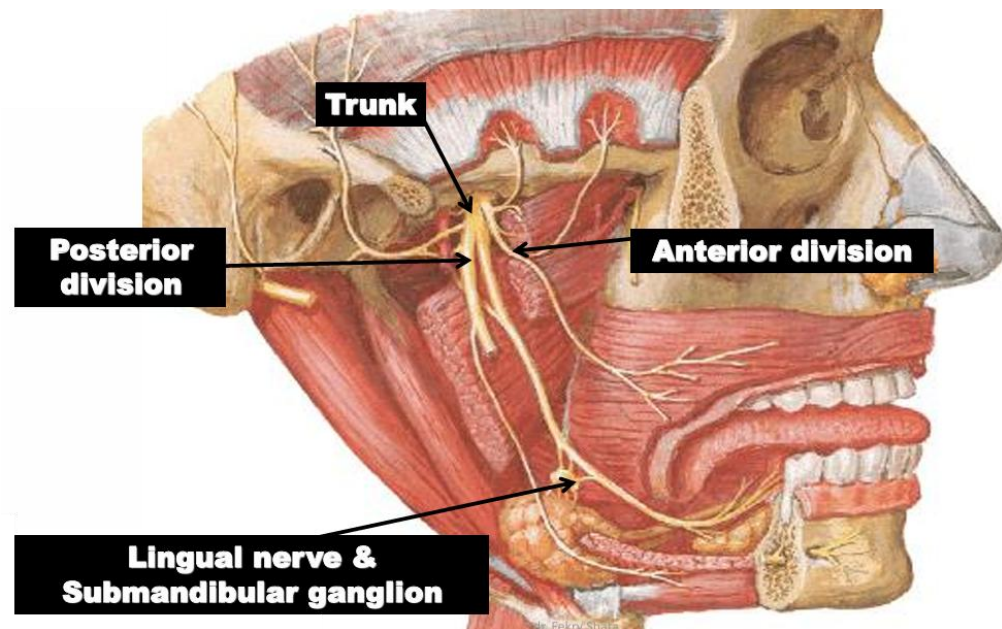
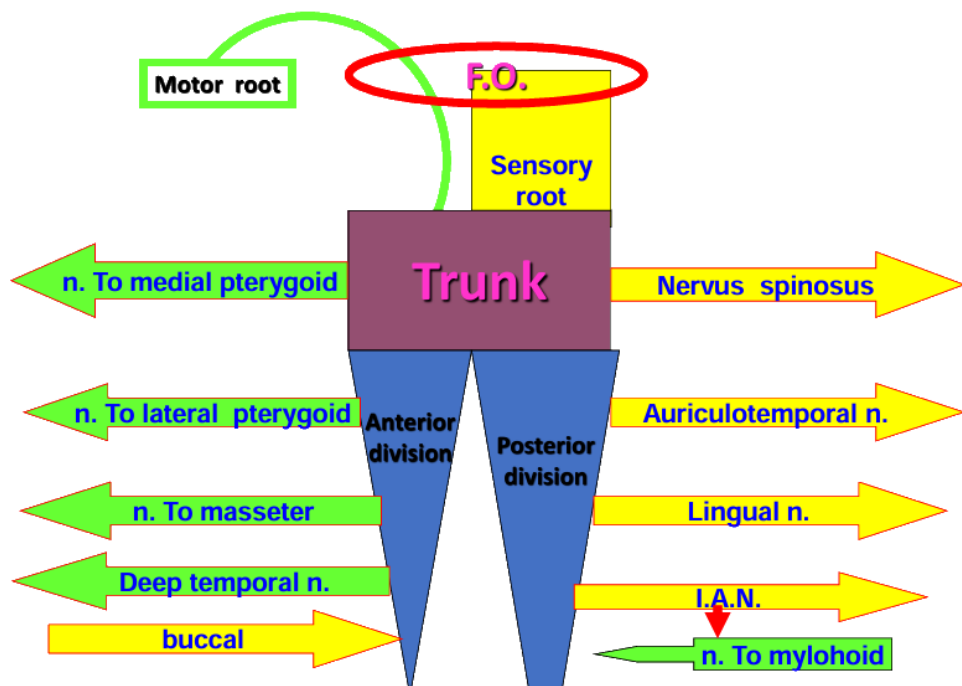
## Divisions of CN V (Maxillary N. [V2])

<b>Size</b>	It is <b>intermediate</b> division of trigeminal nerve.	
<b>Type</b>	Whole Sensory.	
<b>Pathway</b>	<p>Leaves the cranium through <b>foramen rotundum</b>, which is located in the greater wing of sphenoid bone. Once outside the cranium, it crosses the uppermost part of the <b>pterygopalatine fossa</b>, (between the pterygoid plates and the palatine bone).</p> <p>As it crosses the pterygopalatine fossa it gives its branches: (See Pterygopalatine branches)</p> <p>It enters the orbit through the <b>inferior orbital fissure</b>.</p> <p>The infraorbital nerve runs forwards on the floor of the orbit in <b>infraorbital groove</b> → <b>infraorbital canal</b> → <b>infraorbital foramen</b> → the <b>face</b> supplying the skin of the face, nose, lower eyelid and upper lip</p>	
<b>It gives branches when passes in front of:</b>	<b>Cranial Cavity</b>	Meningeal
	<b>Pterygopalatine fossa</b>	<b>Ganglionic</b> – Zygomatic – <b>Posterior Superior Alveolar</b>
	<b>Infraorbital Canal</b>	<b>Middle Superior Alveolar</b> – <b>Anterior Superior Alveolar</b>
	<b>Face</b>	Palpebral – Nasal – Superior Labial



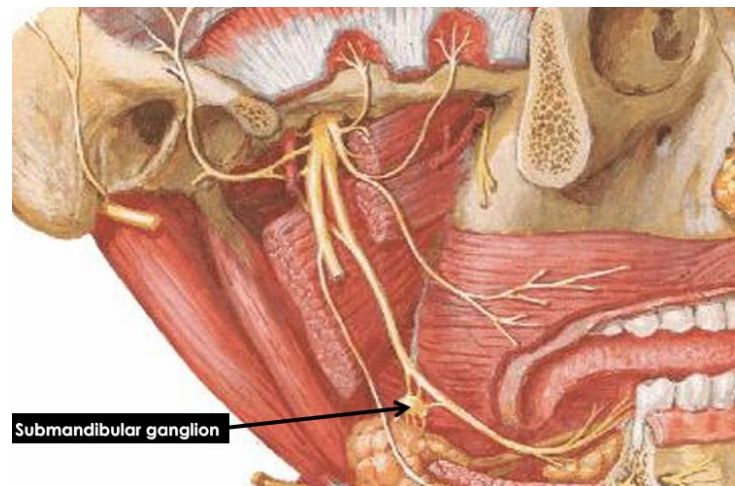
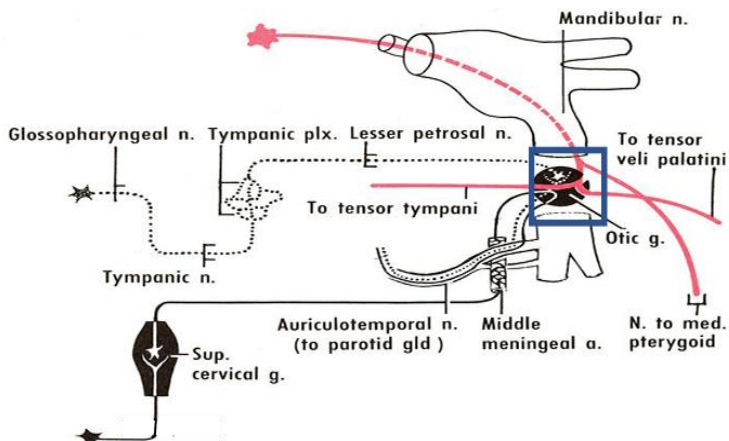
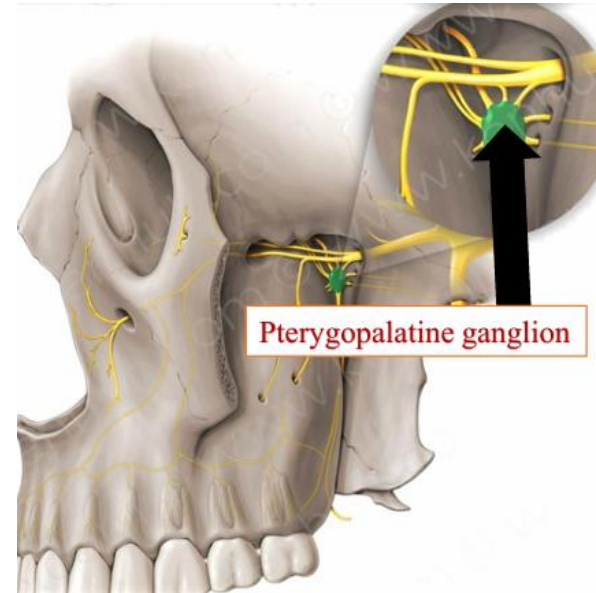
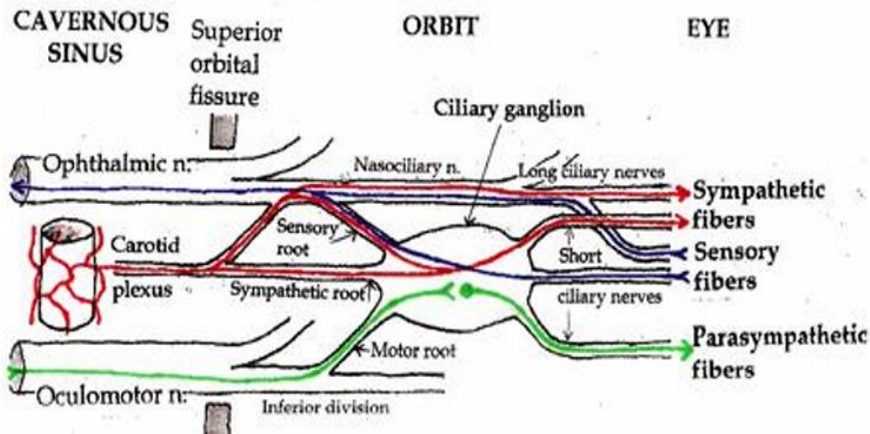
## Divisions of CN V (Mandibular N. [V3])

Size	A <b>small motor root</b>	Passes under the ganglion to unite with the sensory root just outside the skull.
	A <b>large sensory root</b>	Arises from trigeminal ganglia in middle cranial fossa.
Type	<b>Mixed</b> (motor & Sensory)	
Pathway	Passes through <b>foramen ovale</b> → Infratemporal fossa → divides into <b>small anterior</b> and <b>large posterior</b> trunks	
Branches	Trunk	Meningeal (Nervous Spinosus) – Nerve to <b>medial pterygoid muscle</b>
	Anterior Division	Temporal N. – Nerve to <b>lateral Pterygoid Ms</b> – Nerve to <b>Masseter Ms (Motor)</b> Buccal N. ( <b>Sensory</b> )
	Posterior Division	Auriculotemporal N. – <b>Inferior alveolar N.</b> – <b>Lingual N. (Sensory)</b> Nerve to <b>Mylohyoid Ms (Motor)</b>



## Ganglia Associated with CN V

Ganglion	Connected to	Function
Ciliary Ganglion	Nasociliary N. (Ophthalmic N.) (V1)	Accommodation through <b>oculomotor N.</b>
Pterygopalatine Ganglion	Maxillary N. (V2) in infratemporal fossa	Secretomotor fibers to <b>lacrimal gland</b> through <b>Facial N.</b>
Otic Ganglion	Deep to the trunk of mandibular N. (V3)	Secretomotor fibers to <b>parotid gland</b> through <b>glossopharyngeal N.</b>
Submandibular Ganglion	Lingual N. (V3), rest on hyoglossus.	- Supplies posterior ganglionic. - Secretomotor fibers to <b>submandibular and sublingual gland</b> through <b>Facial N.</b>

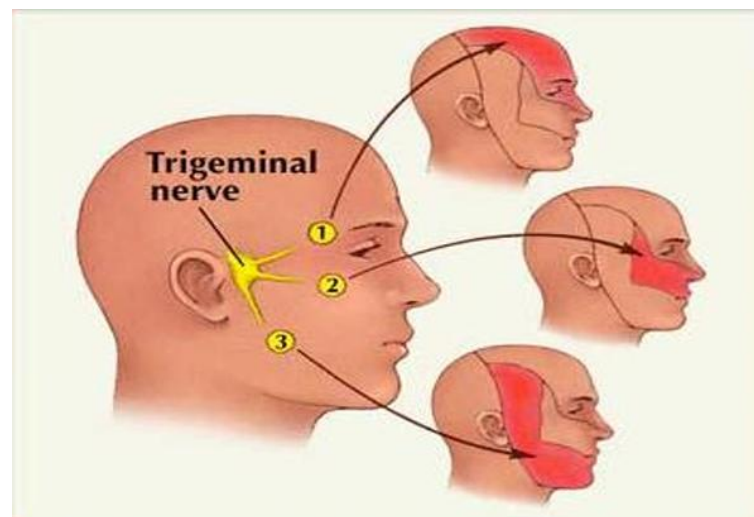
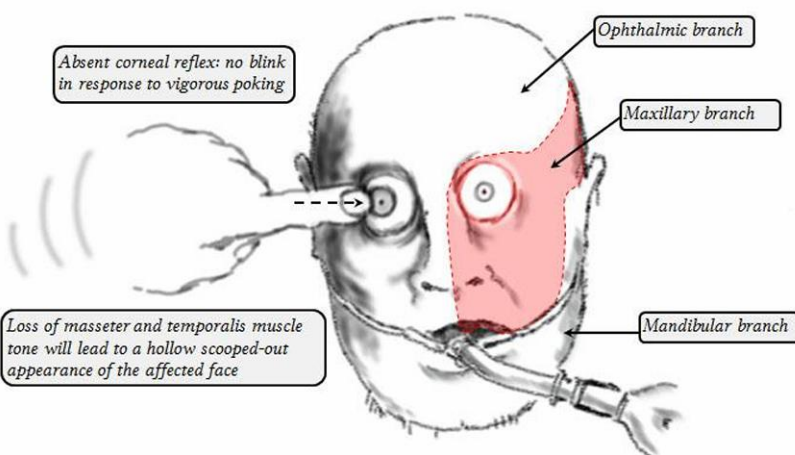


## CN V Lesions

- They cause:
  - **Paralysis** of muscles of **mastication** on the same side of the head.
  - **Loss** of **all sensations** on the same side of the face.

### Trigeminal Neuralgia (Fothergill's disease)

Tic douloureux	Painful jerking uncontrollable facial twitching caused by the pain.
Characters	Sudden, usually unilateral, severe, brief, stabbing, recurring pain in the distribution of one or more branches of trigeminal nerve.
Age & Gender	50Y & Predominates in Females
Provocated by	Touching face at particular site Chewing/Speaking Brushing/Shaving Washing the face
N.B.	The characteristic of the disorder being that the <b>attacks do not occur during sleep.</b>



▪ Quiz:

*1. Paralysis of muscles of mastication on the same side of the head is caused by lesion of which cranial nerve?*

A. 3<sup>rd</sup>

B. 5<sup>th</sup>

C. 7<sup>th</sup>

D. 9<sup>th</sup>

E. 11<sup>th</sup>

Answer: B

*2. Which of the following ganglia is related to lingual nerve?*

A. Ciliary

B. Submandibular

C. Pterygopalatine

D. Otic

E. Genuiculate

Answer: B